

Anatomy 1

Assessment Tasks

This course is assessed through five tasks. One written assignment on the skeletal system, and four practical tests.

You must complete & submit the written task to the massage therapy drop box outside the lifts on the 3rd floor of H-Block by 5pm on the due date listed below.

The practical tests are held at 9am on the Friday morning of each practical block. Non-attendance at these tests will result in a not competent grade unless previously arranged with the programme coordinator.

Task	Subject	Due Date
1	Written Assignment: Skeletal Structure	Friday 30 May 2008
2	Applied Anatomy: Back, Head, Neck	Friday 4 April 2008
3	Applied Anatomy: Shoulder, Upper Arm	Friday 18 April 2008
4	Applied Anatomy: Legs, Gluts	Friday 9 May 2008
5	Applied Anatomy: Lower Arm, Hands, Feet	Friday 30 May 2008

You will be given written feedback on completion of each of the assessments.

If you are unsuccessful, the reassessment policy will be applied.

Resources

Class notes & readings
 Bill Robertson Library
 Massage Clinic
 Textbooks
 Internet

Anatomy 1

Task 1 – Written Assignment: Skeletal Structure

Due Date: 30 May

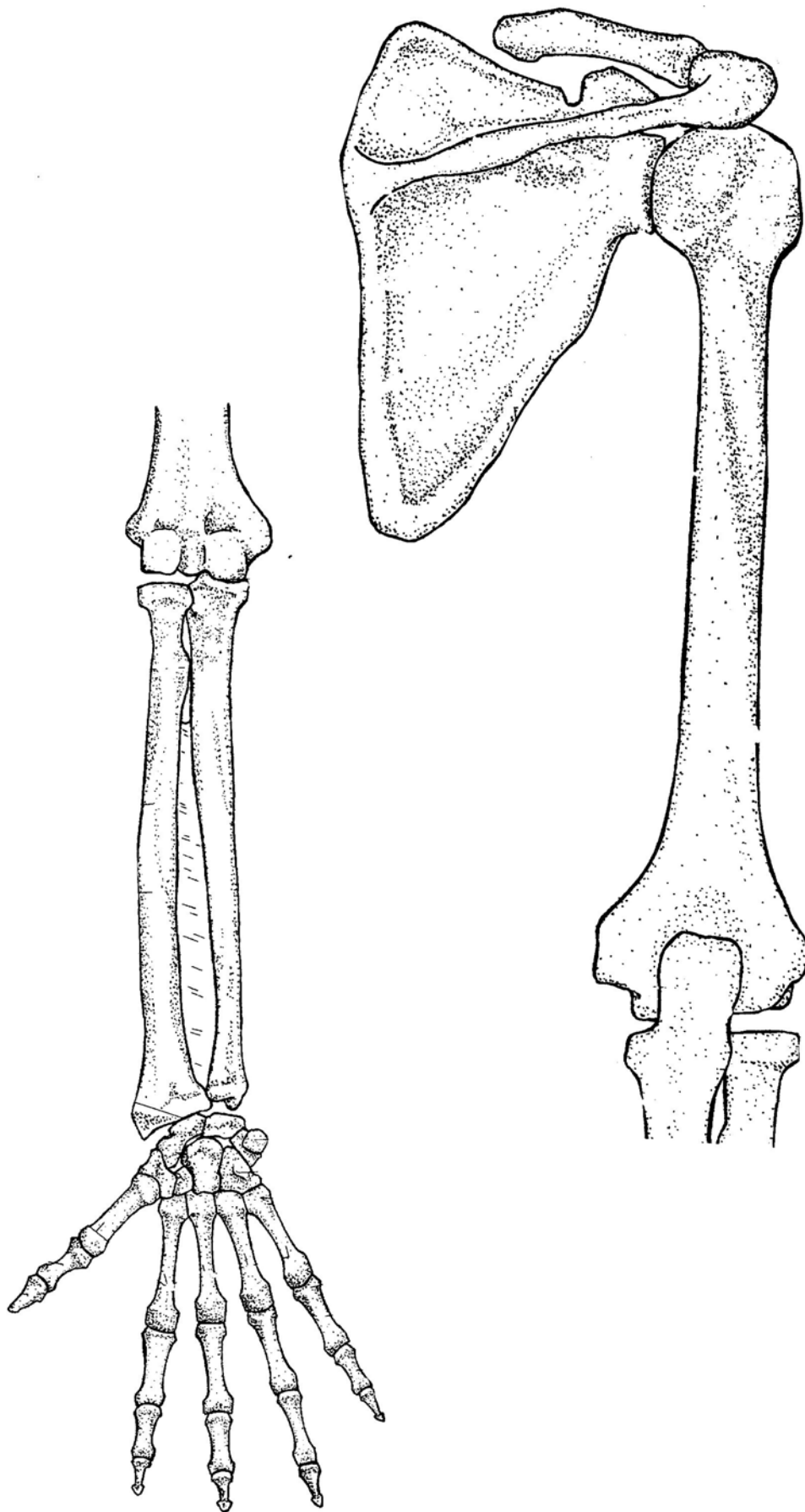
Name: _____

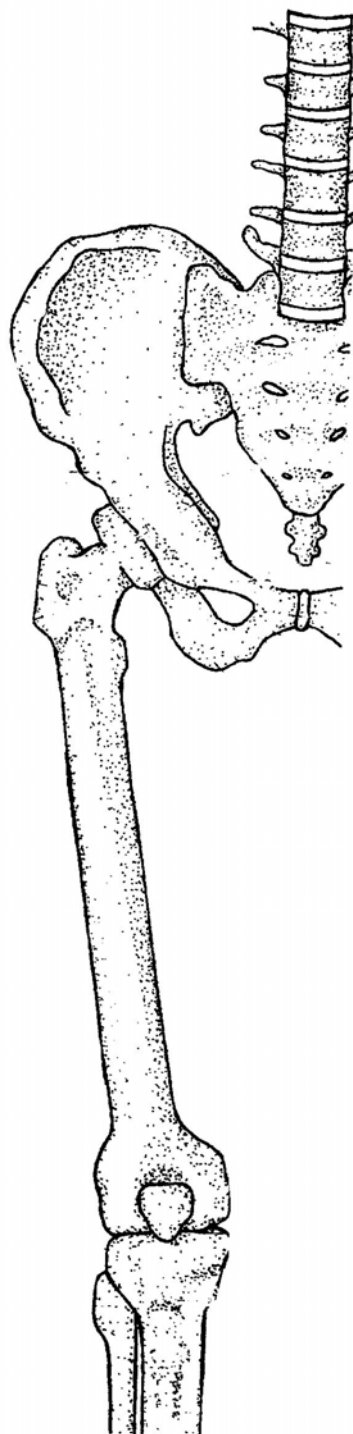
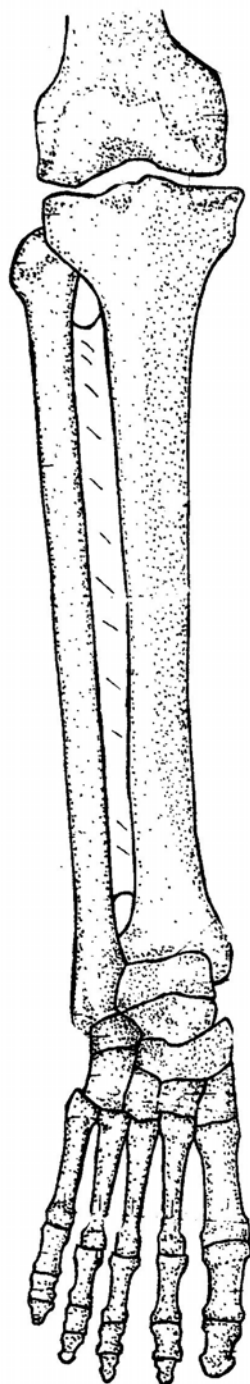
- Briefly **describe** one **distinguishing feature** *and* **identify** one **bony landmark** for each the following bones (US12720, pc 1.5)

Bone	Distinguishing feature	Bony landmark
Humerus		
Radius		
Ulna		
Scaphoid		
Femur		
Patella		
Tibia		
Fibula		
Calcaneus		

- Label the diagrams shown on the following two pages to show the location of these **bony landmarks, ligaments and retinacula** (US 14759, pc 1.2 & pc 1.4)

- | | |
|-------------------------------------|--|
| i. inferior angle of the scapula | xiv. head of fibula |
| ii. vertebral border of the scapula | xv. medial malleolus of tibia |
| iii. spine of the scapula | xvi. lateral malleolus of fibula |
| iv. glenoid cavity | xvii. lateral collateral ligament of elbow |
| v. greater tuberosity of humerus | xviii. flexor retinaculum of wrist |
| vi. deltoid tuberosity | xix. medial collateral ligament of knee |
| vii. lateral epicondyle of humerus | xx. cruciate ligaments |
| viii. head of radius | xxi. lateral collateral ligament of ankle |
| ix. radial styloid process | xxii. medial collateral ligament of ankle (deltoid ligament) |
| x. ulnar styloid process | |
| xi. greater trochanter of femur | |
| xii. adductor tubercle of femur | |
| xiii. tibial tuberosity | |

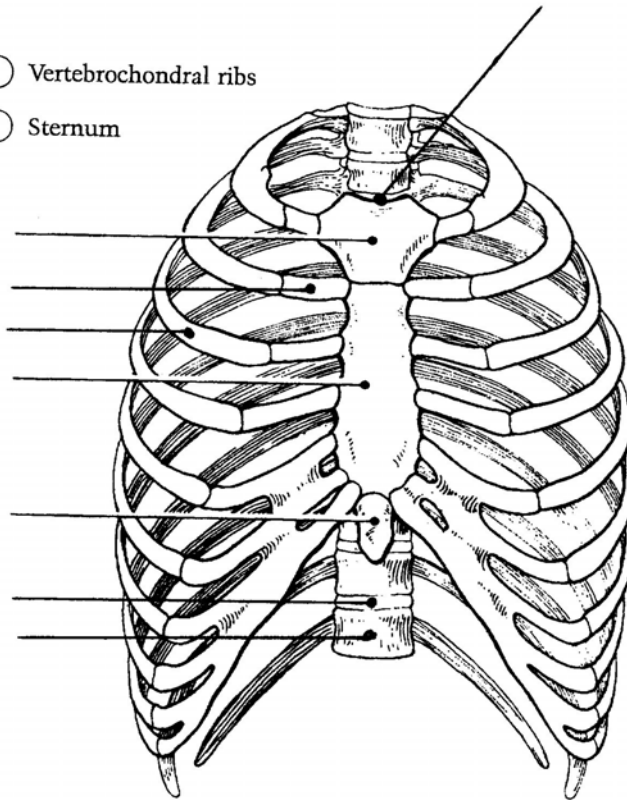




3. The following diagram illustrates an anterior view of the thorax. Select a different colour for each of the structures (and their corresponding coding circles) below. **Label the bony structures and landmarks indicated by the leader lines** (US12720, pc 1.4; US 14759, pc 1.1)

- ☐ Vertebrosteral ribs
- ☐ Costal cartilages
- ☐ Vertebral ribs

- ☐ Vertebrochondral ribs
- ☐ Sternum



4. Complete the following statements about the thorax by inserting your responses in the answer blanks (US12720, pc 1.4; US 14759, pc 1.1)

(i) The bony thorax, or thoracic cage, consists of the _____
_____ posteriorly , the _____ laterally , and the _____
and _____ anteriorly.

(ii) The general shape of the thoracic cage is that of an _____
_____.

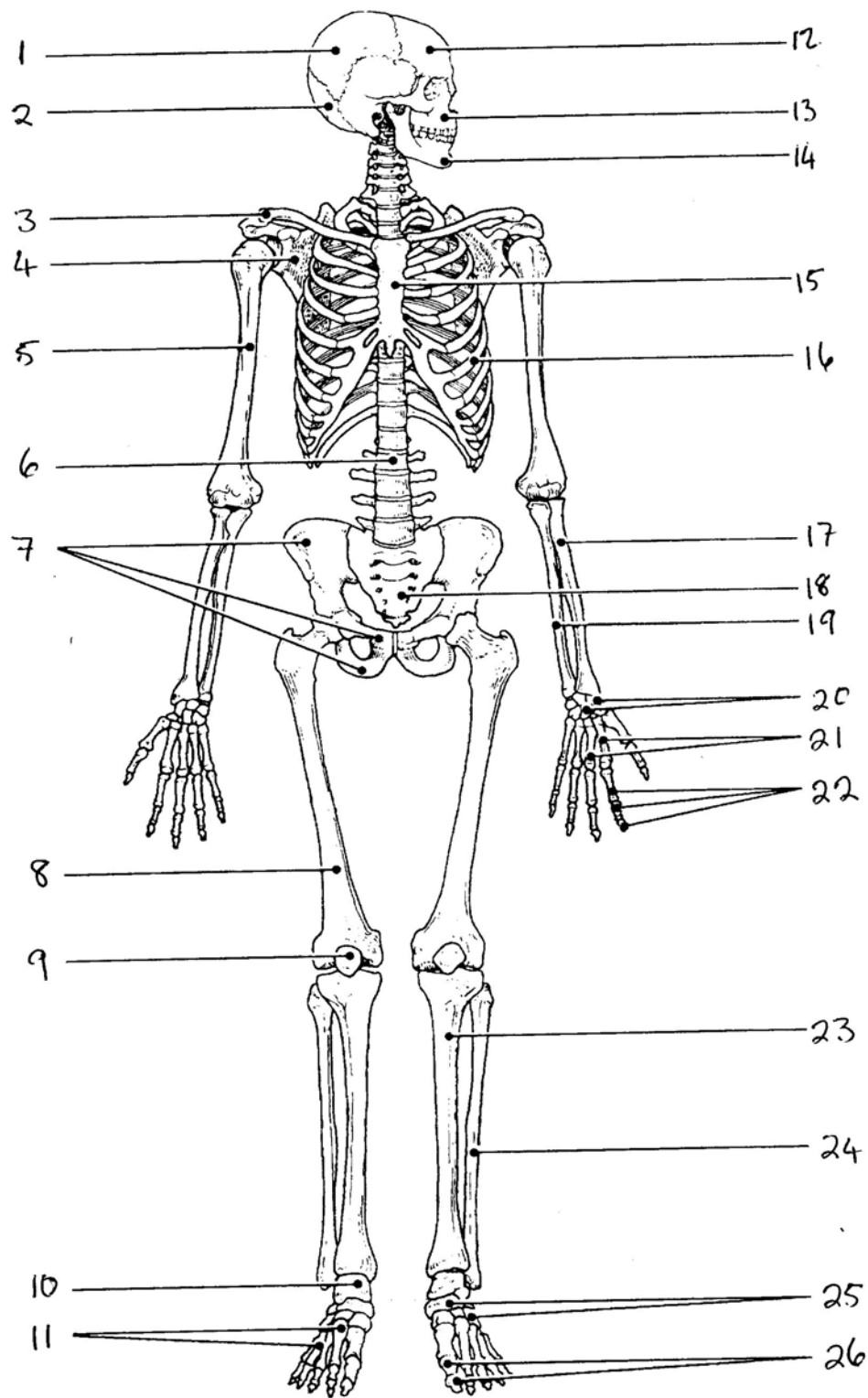
(iii) Two functions of the bony thorax are _____ and
_____. The organs protected by the thoracic cage
include the _____ and the _____ .

(iv) Ribs 1-7 are commonly called _____ or
_____ ribs, whereas ribs 8-12 are called _____
or _____ ribs. All ribs articulate posteriorly with the
_____ and most connect anteriorly to the
_____, either directly or indirectly.

(v) The _____ connect the _____ to the
sternum.

5. Name the bones or groups of bones indicated by the numbers in the diagram shown on the following page (US12720, pc 1.5)

- | | |
|-----------|-----------|
| 1. _____ | 2. _____ |
| 3. _____ | 4. _____ |
| 5. _____ | 6. _____ |
| 7. _____ | 8. _____ |
| 9. _____ | 10. _____ |
| 11. _____ | 12. _____ |
| 13. _____ | 14. _____ |
| 15. _____ | 16. _____ |
| 17. _____ | 18. _____ |
| 19. _____ | 20. _____ |
| 21. _____ | 22. _____ |
| 23. _____ | 24. _____ |
| 25. _____ | 26. _____ |



6. Describe the structure and function of the **VERTEBRAL COLUMN**.

Illustrate your answer with diagrams with reference to **range of motion, movement** and **bony landmarks, ligaments and retinacula**. (US12720, pc 1.3)

Anatomy 1

Tasks 2 - 5 – Applied Anatomy

The applied anatomy assessments will take place at 9am on Friday morning. You will be assigned another student to work with, and an assessment time. At the time assigned you and your partner will assemble in the foyer of the student clinic & will be shown into one of the clinics.

Your lecturer will assess your knowledge of anatomy by requiring you to locate and palpate a range of bony landmarks, muscles, and attachment sites which they will select from the items on their assessment schedule. The assessment schedules for each test are available at www.wikieducator.org/Therapeutic_massage/Year_1_Assessment. It is highly recommended that you familiarise yourself with these assessment schedules and test each other before each applied anatomy test.

Task	Assessment	Filename	Date of assessment
2	Applied Anatomy: Back, Head, Neck	Anat1-2.pdf	Friday 4 April 2008
3	Applied Anatomy: Shoulder, Upper Arm	Anat1-3.pdf	Friday 18 April 2008
4	Applied Anatomy: Legs, Gluts	Anat1-4.pdf	Friday 9 May 2008
5	Applied Anatomy: Lower Arm, Hands, Feet	Anat1-5.pdf	Friday 30 May 2008

This is a closed book assessment

Non-attendance at any test will result in a not-competent grade for the Anatomy 1 course unless previously arranged with the programme coordinator.